

Full maxillary rehabilitation with immediate implant placement of NEVO RC INICELL[®] implants in Type 3 bone

Dr Mathieu Rousset, France

The emergence of fully digital workflows in implant dentistry has revolutionised the way clinicians approach complex rehabilitative cases. Achieving high primary stability in low-quality bone, such as Type 3 or 4 bone (Lekholm & Zarb 1985), has traditionally posed significant challenges. However, advancements in implant design, surgical techniques, and digital imaging have enabled the successful placement and immediate loading of implants even in these challenging scenarios. The following case report presents a comprehensive approach to full maxillary rehabilitation using immediate implant placement in Type 3 bone, leveraging modern digital tools and the innovative and gentle NEVO implant design to achieve healthy and satisfying clinical outcomes.

Case presentation

A 64-year-old male patient with good general health presented with a long history of wearing a removable prosthesis, seeking a fixed solution to enhance both function and aesthetics. Upon clinical and radiological examination, it was clear that the patient had four remaining teeth in the maxilla not worth keeping that needed extraction (Figs. 1 & 2). Additionally, the bone quality was classified

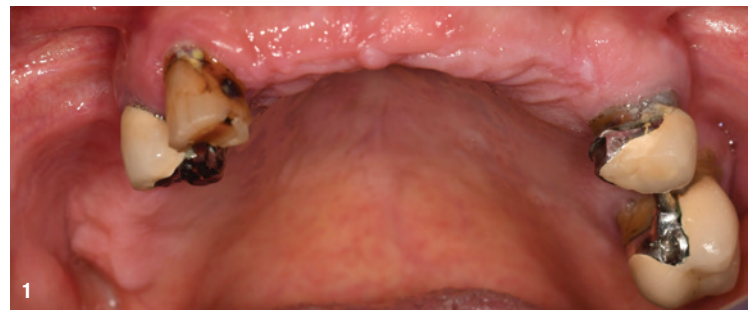

Fig. 1: Preoperative condition of the maxilla.

as Type 3, indicating low bone density and presenting challenges for implant placement, particularly in achieving primary stability. After thorough discussion of all the available options, the patient opted for an all-on-six approach with immediate implant loading.

Preoperative planning

Detailed preoperative planning was critical for the success of this case. Using advanced 3D imaging technology and planning software (PDIP, Carestream Dental),

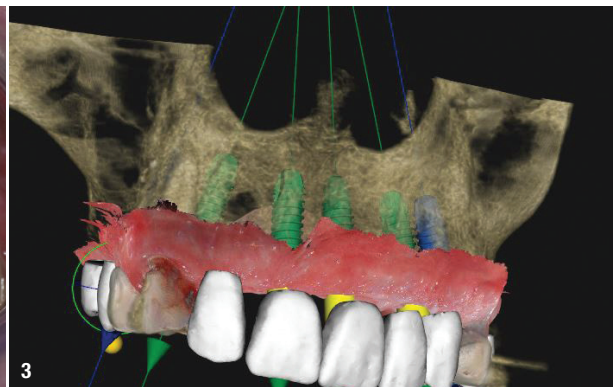
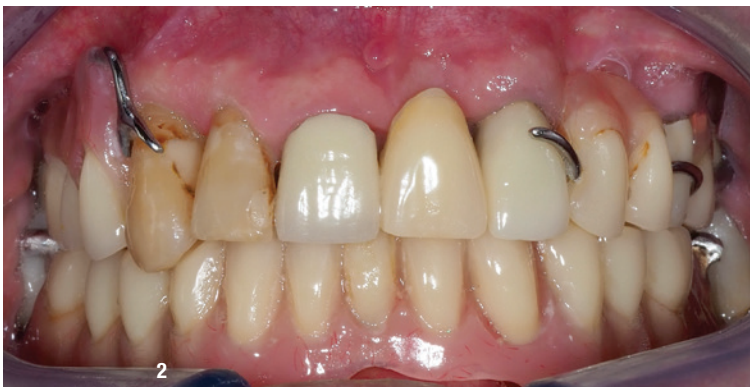

Fig. 2: Full-mouth image taken preoperatively. Fig. 3: 3D surgical planning.*

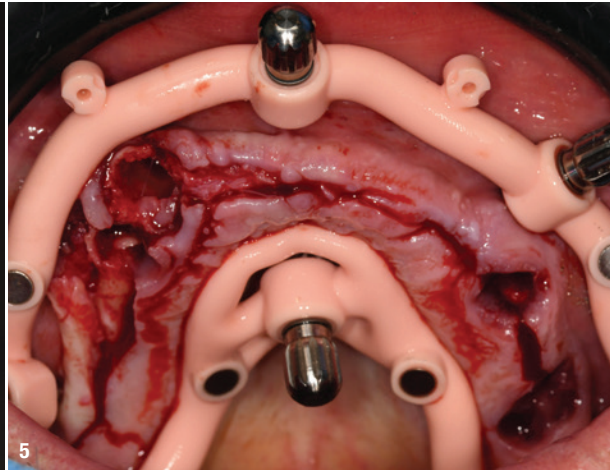
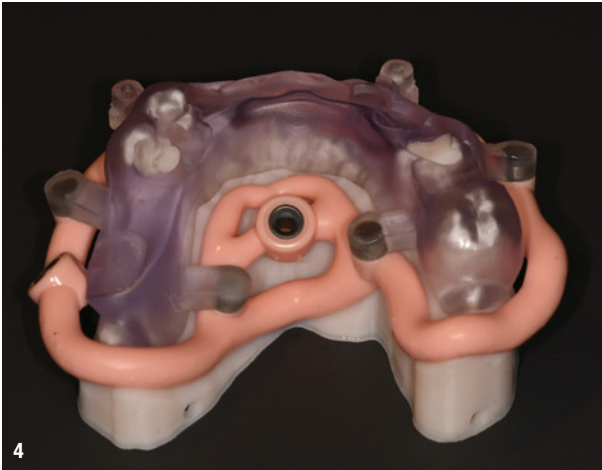

Fig. 4: Stackable surgical guide (designed using RealGUIDE™ by Genesis Dental Lab).* **Fig. 5:** Flap elevation following guide fixation.

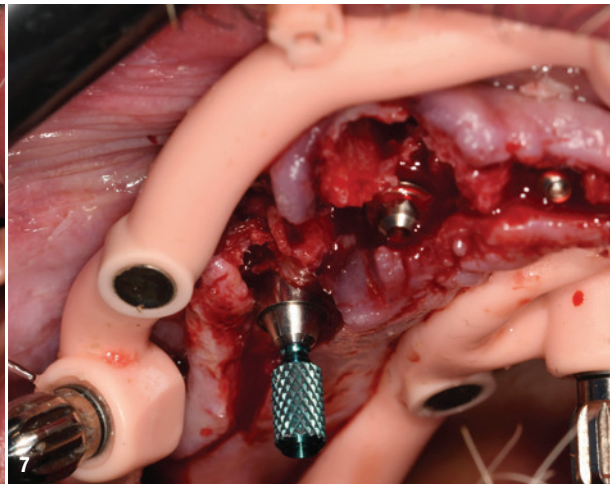
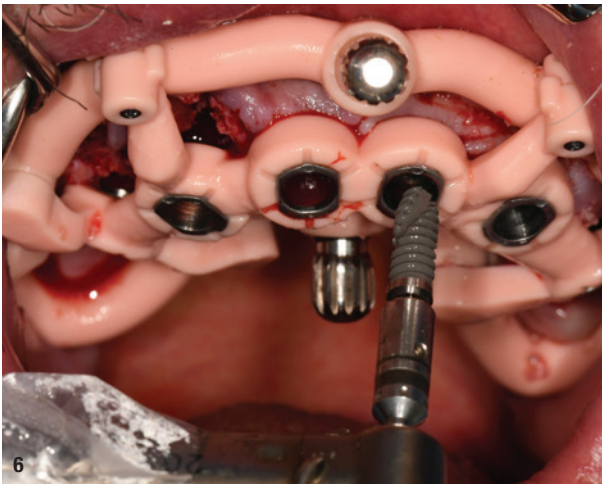


Fig. 6: NEVO RC INICELL® implant placement using the surgical guide. **Fig. 7:** Placement of VARIOmulti abutments.

a comprehensive virtual treatment plan was developed and showed to the patient (Fig. 3)*. The planning procedure included the design of a stackable surgical guide system comprising the position guide, base guide, and drilling guide (Fig. 4)*. This guide would ensure precise implant placement, crucial for achieving optimal outcomes in a case with compromised bone quality.

Surgical procedure

The surgical procedure commenced with the stabilisation of the base guide using four anchor pins (MIS), providing a secure and accurate reference for subsequent steps. A flap was raised to expose the underlying bone, followed by the extraction of the four remaining teeth (Fig. 5).

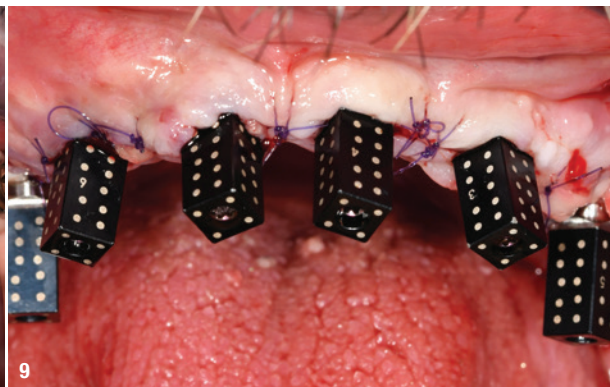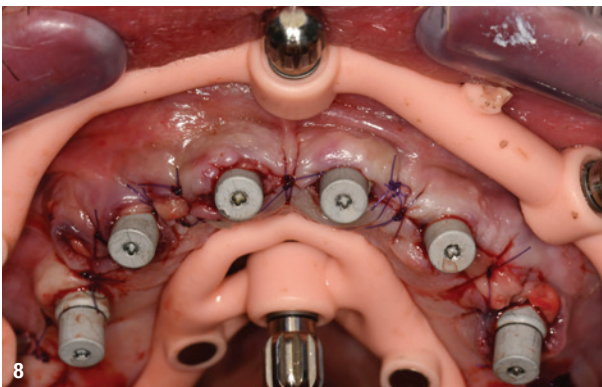


Fig. 8: Optical impression with scanbodies and sutured flap. **Fig. 9:** Additional photogrammetry to ensure maximum accuracy.

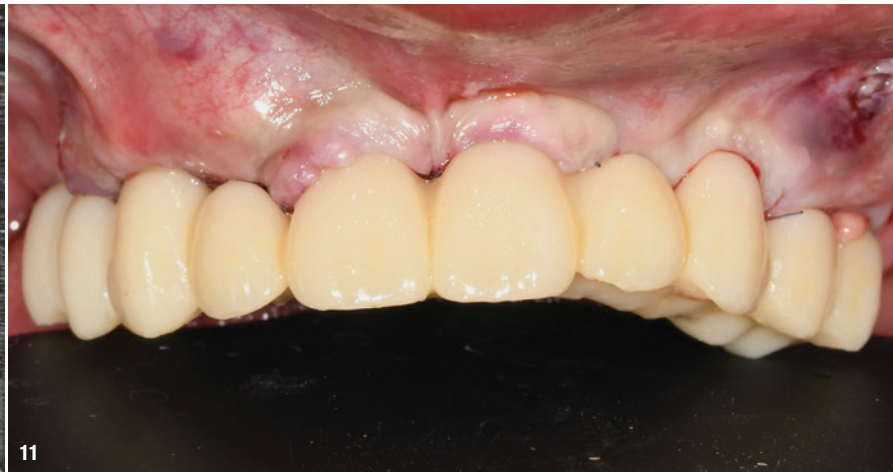
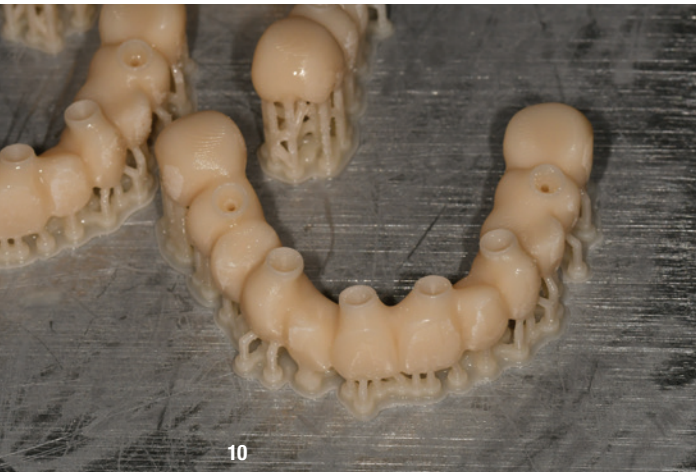
Fig. 10: Chairside fabrication of the temporary prosthesis. **Fig. 11:** Temporary prosthesis placement six hours postsurgery.

Following tooth extraction, six implant beds were prepared according to the manufacturer's guidelines. The implant beds in the four extraction sockets were only partially drilled to allow for high primary stability in the poor-quality bone. Six NEVO RC INICELL® implants (Thommen Medical) were then placed into the prepared implant beds through the drilling guide (Fig. 6). Despite the poor bone quality, the immediately placed implants in extraction sockets achieved an Implant Stability Quotient (ISQ) of 73, indicating sufficient initial stability for immediate loading.

Prosthetic procedure

VARIOMulti abutments (Thommen Medical) were placed on all implants, with two posterior abutments angled at

17 degrees to accommodate the anatomical structure and prosthetic requirements (Fig. 7).

To address the bone defects and enhance stability, grafting was performed using "sticky bone" (Porcin hydroxyapatite, REGEDENT).

With the implants and abutments in place, attention turned to the prosthetic phase (with kind support of Genesis dental lab, Bordeaux, France). Scanbodies were inserted, the flap was sutured, and an optical impression was taken (Fig. 8). The base guide remained *in situ* during the impression to ensure precise repositioning, facilitating accurate model creation by the dental technician. Given the size and complexity of the implant-supported

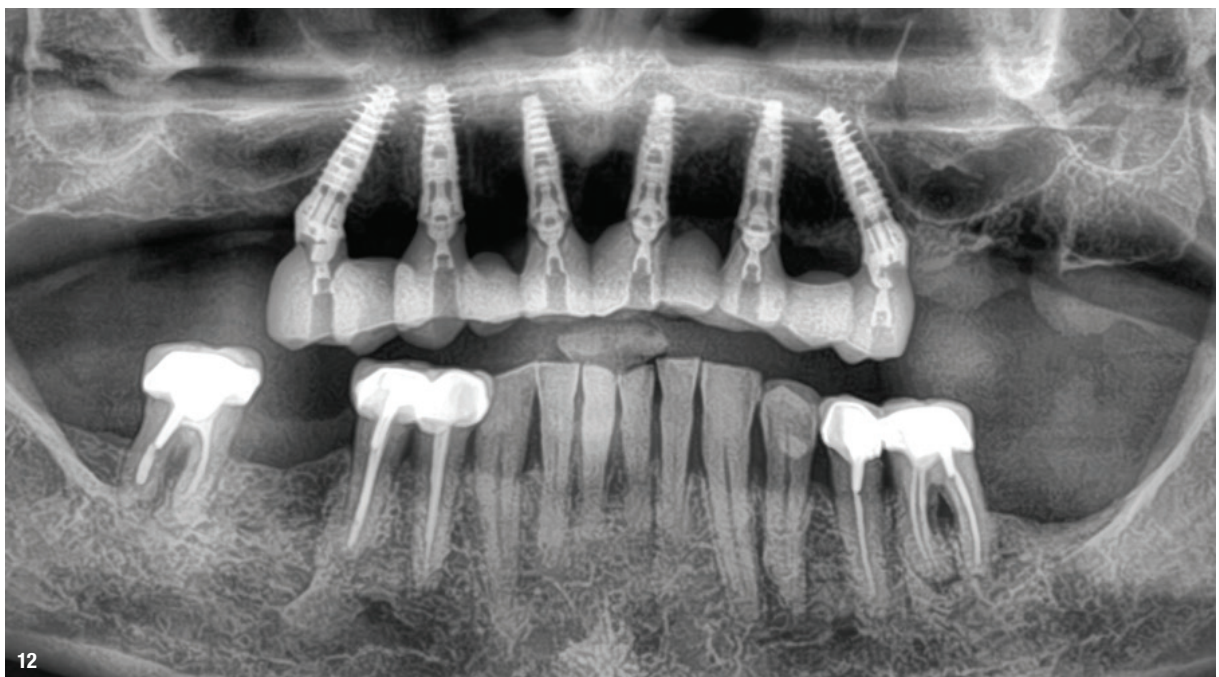
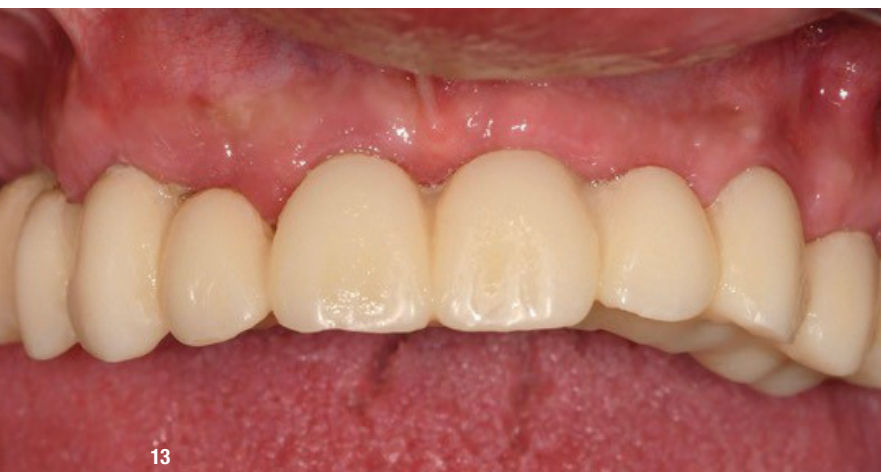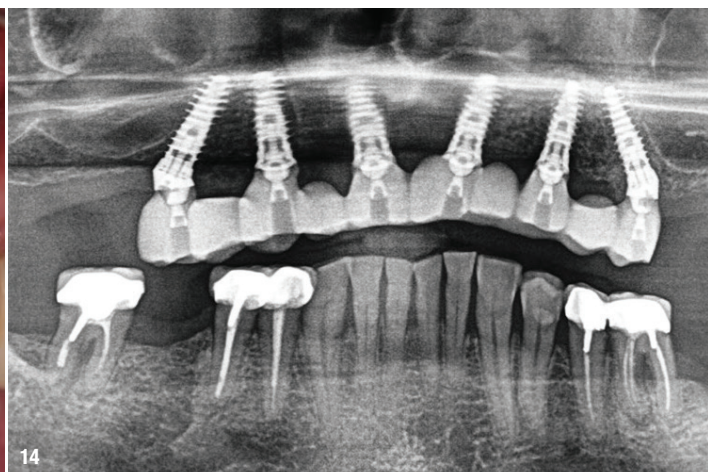


Fig. 12: Post-placement radiograph of the temporary prosthesis.



13



14

Fig. 13: Clinical image three months postsurgery, showing healthy soft tissue. **Fig. 14:** Radiograph three months postsurgery, demonstrating stable bone levels.

bridge, additional photogrammetry was employed to achieve the highest possible accuracy (Fig. 9). This technique provided a precision of less than 15 microns, essential for the passive adaptation of the prosthetic framework.

A temporary full arch bridge was designed and printed chairside within one hour (3D printer, SprintRay), leveraging modern digital dentistry technologies (Fig. 10). The temporary prosthesis was installed six hours after surgery, providing immediate functional and aesthetic benefits to the patient (Fig. 11). The radiograph image showed good bone levels after placement (Fig. 12).

Postoperative results

The postoperative period was uneventful, with the patient exhibiting excellent healing and adaptation to the temporary prosthesis. After three months, clinical and radiographic evaluations showed healthy soft tissues and stable bone levels around the implants (Figs. 13 & 14). The success of the immediate implant placement and the use of advanced surgical guides and photogrammetry underscored the effectiveness of the treatment protocol.

Conclusion

This case highlights the successful full maxillary rehabilitation achieved through immediate implant placement in Type 3 bone. The use of NEVO RC INICELL® implants, with their unique and gentle cylindrical-tapered shape, was pivotal in achieving high primary stability without compromising the bone, even in a compromised bone environment. This immediate loading protocol was further supported by the integration of 3D planning, precise surgical guides, advanced grafting techniques, and digital prosthetic workflows. Together, these modern techniques enabled the delivery of a high-quality, fixed solution in a single surgical session. The patient's satisfaction

and the clinical outcomes underline the potential of modern implant dentistry to effectively address complex cases with compromised bone conditions.

* Planning was performed with ELEMENT implants (Thommen Medical) due to limited availability of NEVO in the planning software ahead of its full market release. ELEMENT and NEVO implants share the exact same outer implant body contour.

about the author



Dr Mathieu Rousset operates in his private practice in Brive la Gaillarde, France. With additional qualifications in biomaterials, oral surgery, and computer-assisted dentistry, he has refined his practice to specialise exclusively in implantology. Dr Rousset has established the training center Association Malemortoise de Parodontologie et Implantologie

Orale (AMPIO) within his practice, in which he teaches implantology with a focus on guided surgery and digital dentistry. In addition, he holds a teaching position in digital dentistry at the Diplôme Universitaire Européen (DIUE) d'Implantologie in Corsica, emphasising his passion for sharing knowledge and shaping the future of dental professionals.

contact

Dr Mathieu Rousset

Association Malemortoise de Parodontologie et Implantologie Oraie
2 rue de la Paix
19360 Malemort, France
AMPIO.formaton@icloud.com
www.ampioformaton.com